

The use of the Erbium Yttrium Aluminium Garnet (2940nm) in a Laser-Assisted Implant Therapy

How far we can push the envelope?

author_Dr Avi Reyhanian

Abstract

The array of available clinical applications for laser assisted dentistry is growing rapidly, with the greater number of applications being for oral surgery. Er:YAG laser wavelength is considered to be extremely safe, and is the dominant wavelength in dentistry today. Er:YAG is one of the most suitable wavelengths for bone applications. The presentation will demonstrate the use of the Er:YAG laser in the world of implantology, and the advantages vs. conventional treatment methods. The purpose in this paper is to put some order into the chaotic information surrounding the subject and to provide some answers to the most common and frequent questions we often meet: How far we can go with this technology? Is it just a marketing tool or proven therapy? Where is the line between reality and

fantasy? Does the new technology completely replace the conventional methods and if not, at which point do we lay the laser's hand piece down and re-employ the "old" tools and conventional ways?

The article will exhibit, beyond any doubts, that Er:YAG laser is very valuable tools and shows promise and safe as an effective new technical modality for implant therapy.

Introduction

Osseo-integration dental implants have become a routinely recommended procedure in the clinical practice of dentistry 1-4, and have been utilized as a successful treatment modality over three decades, with a reported success rate of greater than 90% 5-7,8. The predictability and success of dental implants has

Fig. 1_intrasulcular incision

Fig. 2_Midcrestal incision

Fig. 3_vertical incision for release

Fig. 4_Semi lunar incision

Fig. 5_Granulation tissue

Fig. 6_The erbium to ablate the granulation tissue

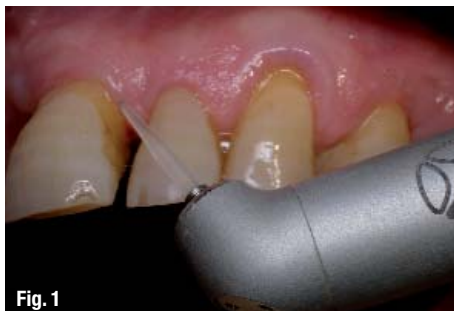

Fig. 1

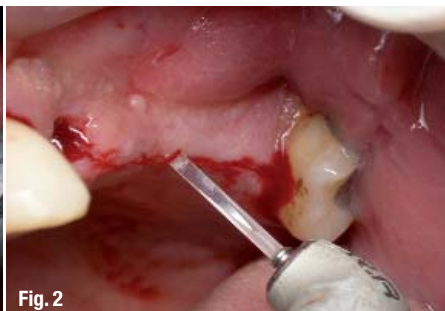

Fig. 2

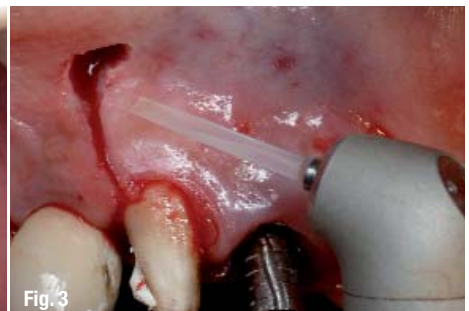

Fig. 3

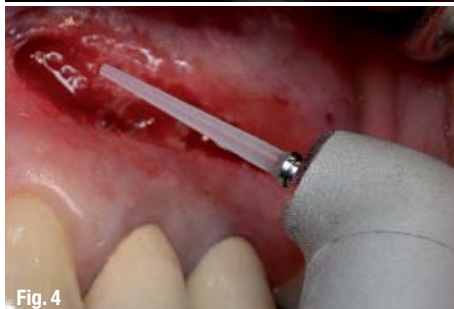

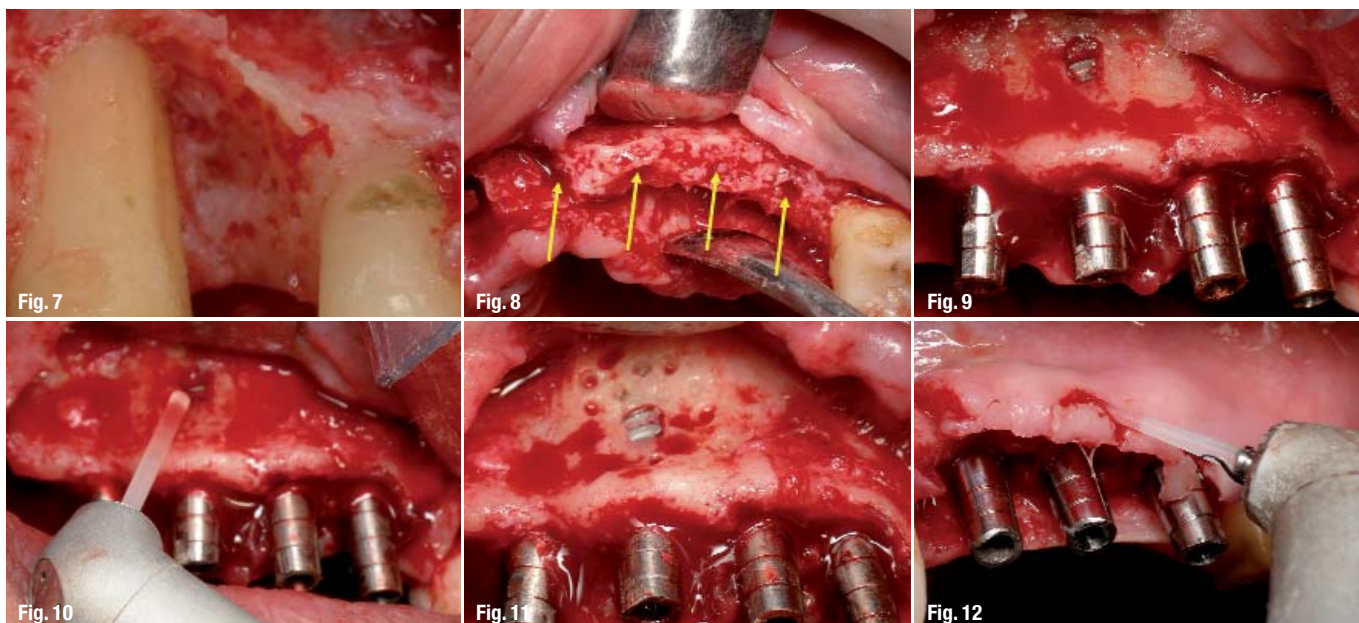
Fig. 4

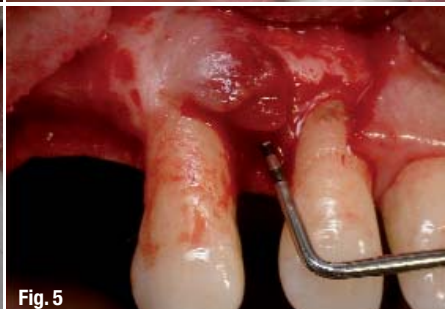

Fig. 5

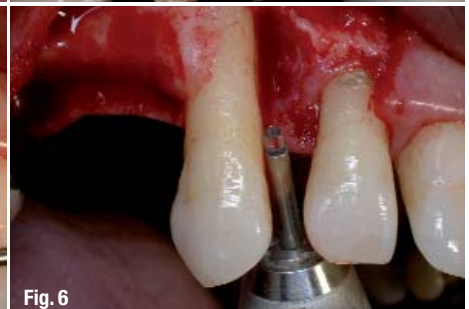

Fig. 6



secured their place as a standard treatment modality. This technique using the Er:YAG laser presents several advantages vs. conventional treatment methods, and there are minimal post-operative complications coupled with a high rate of success. The Erbium :YAG is one of the most suitable wavelength for bone applications. The Erbium's energy is highly absorbed in the water component of dental tissue and provides efficient ablation without the risk of significant thermal damage.¹³ The Er:YAG laser is a thermal laser wavelength which is located in the infrared zone of the electromagnetic spectrum, considered to be extremely safe. Most of the procedures performed at my practice are in the realm of surgery and they are all performed with the Er:YAG laser: Today we can observe an inordinate lack clarity concerning the clinical uses of the laser in the field of implantology, and with many doctors in the field reality does indeed mix with fantasy.

What do we know about the Er:YAG laser- 2940 nm

The Erbium Yttrium Aluminium Garnet laser has a wavelength of 2940 nanometres' and emits as a free-running pulsed train of photons in the mid infra-red portion of the electromagnetic spectrum. Got FDA approval for hard tissue in 1997. This laser is a thermal laser: interaction between the laser beam and the target tissue create heat. Successive laser pulses are 100-200 microseconds in width. The prime chromophore of this laser wavelength is water, which makes it appropriate for ablating both hard and soft oral target tissue. Incident laser energy is absorbed by the chromophore, converted into thermal energy which results in expansive vaporisation by micro explosions. Such action causes a dislocation of the tissue structure and ablation; often this is accompanied by an audible "popping" sound. Established high safety in clinical use. The erbium laser presents availability of water

cooling: Extremely low thermal damage to surrounding tissue. Can be used in contact or noncontact mode, efficient ablation effect for both soft and hard tissue. Delivery system- articulated arm (Fotona), hollow wave guide (Lumenis) , fiber optic (Biolase, Doctor smile, Hoya combo,) or no delivery system (Lite-Touch, Syneron medical ltd)

What Can We Actually Do Today ,2009, with the Er:YAG Laser, In the World of Implantology

- 1- Incision- Midcrestal, Vertical , Intrasulcular (Fig. 1,2,3, 4)
- 2- Removal of granulation tissue. (Fig. 5, 6, 7)
- 3- Marking the location and direction of the implant – Only lase at the cortical bone. (Fig. 8)
- 4- Decortication and GBR technique. (Fig. 9, 10, 11)
- 5- Reshaping of the soft tissue (flap) around the implants. (Fig. 12, 13, 14)
- 6- Uncovering of submerged implants. (Fig. 15, 16)
- 7- Flapless implants. (Fig. 17, 18, 19, 20)
- 8- Open sinus lift- Opening the window. (Fig. 21, 22)
- 9- Periimplantitis treatment. (Fig. 23, 24, 25)
- 10- Implant failure treatment. (Fig. 26, 27)
- 11- Immediate implants in infected sites. (Fig. 28, 29, 30, 31)

1- The Erbium laser can make an incision for flap lifting 9-13, such as a crestal incision, or an intrasulcular or vertical release incision. The laser produces a wet incision (some bleeding) as opposed to the dry incision (no bleeding) that is produced by the CO2 laser. The tip of choice is chisel tip or 200 micron tip, contact mode, set power 300mj/25pps (7.5 watt.) When performing the vertical incision, not to push the end of the sapphire tip into the soft tissue but rather to gently stroke the tissue with the tip. The doctor should lase

Fig. 7_ The site image immediate post-op

Fig. 8_ Marking the location of the implant

Fig. 9_ Fenestration

Fig. 10_ The erbium for decortication

Fig. 11_ Decortication

Fig. 12_ Recontouring of the soft tissue around the implants

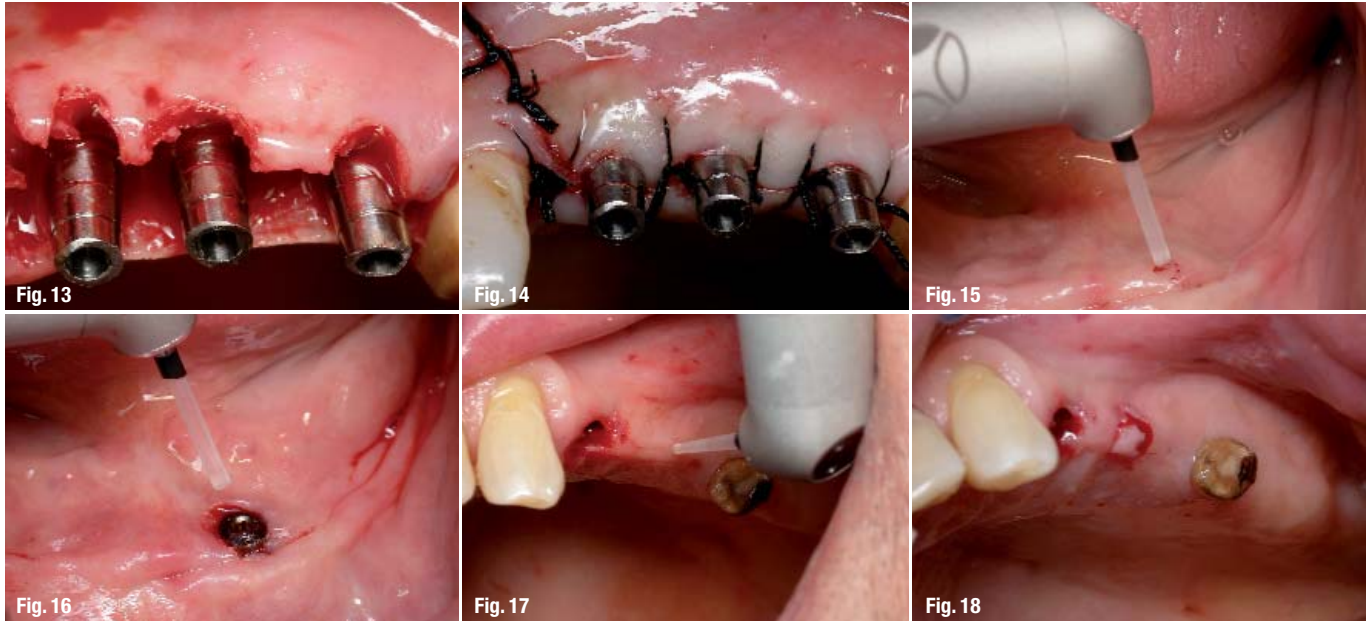


Fig. 13_immediate post op

Fig. 14_final result

Fig. 15_The erbium to uncover the submerged implant

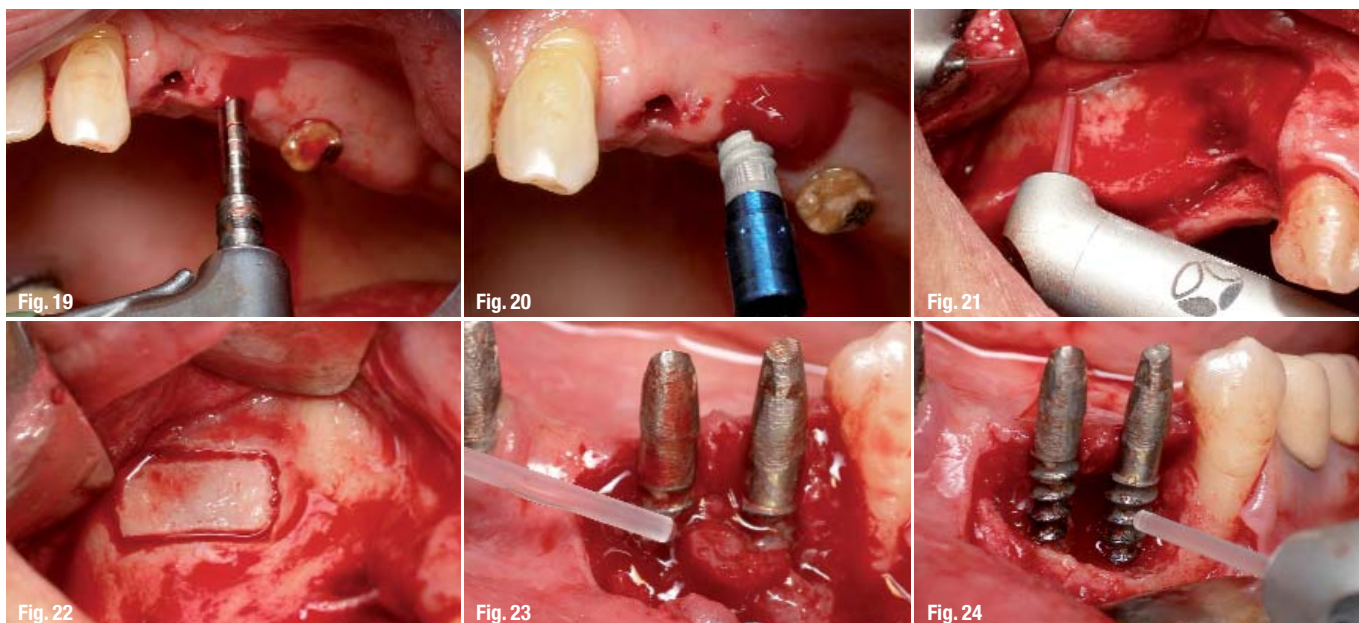
Fig. 16_The uncovered implant

Fig. 17_The erbium to lase the soft tissue

Fig. 18_The soft tissue after lasing with the erbium

the soft tissue until he feels the contact with the bone. 2 Vaporization of granulation tissue 13,15 (if any exists) after raising a flap is efficient with the Erbium laser, with a lower risk of overheating the bone 13,16,17 than those posed by the current diode or CO₂ lasers. Chosen laser is Er:YAG (LiteTouch, Syneron medical ltd). Tip of choice is 1300 micron, noncontact mode (Distance between end of the tip and target tissue = 1.5 mm) set power 400mj/ 17pps = (6.8 watt). It is important to vaporize the granulation tissue before drilling for the implant because one of the reasons for IPL (Implant peri-apical lesion) is insertion of soft tissue into the site preparation for the implant. 3 Using the Erbium laser in non-contact mode (1.5–2 mm from the target tissue), the future location and angle of the implant is outlined; and the laser is used only on the cortical bone. Set power: 300mj/20 pps (6 watt). As an important point of clarification, the laser does not replace the pilot drill; it is used to create a "pilot hole" for the drill. The entire length of the implant is not lased with the laser. This technology doesn't give, yet, the answer to the question how to lase all the entire length of the implant with out the use of rotary instruments. Although there are some dental lasers users with a lot of experience who claim that they lase all the entire length of the implant with the erbium. This statement raise 2 main concerns: The first one is how to control the depth and the second one, Which is the the fundamental concern in any bone surgical procedure, is how to limit thermal rise to within 470C 18 in order to avoid damage to cellular components of bone metabolism and delayed healing 19. Further clinical and basic investigations are require to establish the clinical effectiveness and safety of the Er:YAG laser in implant site preparation. We are not there yet although Er:YAG laser can promote the growth of new bone around placed titanium implants and better osseointegration

compared to the conventional osteotomies, and results of a study 20 indicated that in the rat model the lased bone prepared implant sites vs. conventional bone preparation sites developed a statistically higher percentage of bone-to-implant contact. 4 One of the golden rules for GBR-Guided Bone Regeneration is to Provide a good blood supply – Cortical stimulation: To perforate the cortical bone to get bleeding which bring with him mesenchimal cells, they transform to osteoblasts, they transform to osteocits which are responsible for bone formation. Decortication is performed with the erbium laser (LiteTouch, Syneron medical ltd). The tip of choice is 1300 micron, Set power 300mj/25pps (6 watt). Noncontact mode. No rotary tool vibrations: reducing patient discomfort and enhancing the surgical site. Less stressful oral therapy with enhanced outcomes. 21, 15 5 Dental implant must form and maintain integration not only with bone but also with connective tissue and epithelium- The Junctional epithelial attachment is an important component of the protective permucosal soft tissue seal and may even limit the apical spread of marginal inflammatory that can lead to bone loss or implant failure. If there is enough keratinized tissue, before closing the flap it is recommended to reshaping the soft tissue (flap) around the implants in order to get a better sealing. Tip of choice 200 micron, contact mode, Set power 250mj/30pps (7.5 watt). 6 Implant exposure can be done with the Er:YAG, with the Diode and with the co₂ laser or other wavelengths. The big advantage of the erbium in this procedure versus the others is less zone of thermal necrosis because of the water spray cooling. The benefits of laser use over scalpel include precision, incisional hemostasis and immediate post-operative protection through a tenacious coagulum surface 22, 23 Local anesthetic may or may not be used, depending on patient and opera-



tor preference. A small cone of tissue is removed until near-contact with the screw is made. Tip of choice can be the 200 or 400 or 600 or 800 or 1000 micron. The set power is around 6 watt. 7 In those crests in which the width is more than 7 mm, it is possible to insert the implant without raising a flap. With the erbium laser a small cone of tissue is removed with the diameter of 6 mm. (Tip sapphire 800 mic, contact mode, set power 300/25pps= 7.5 watt). With the 1300 mic sapphire tip, in non-contact mode (1.5-2 mm from the target tissue), the future location and angle of the implant is outlined; and the laser is used only on the cortical bone. Set power 300mj/25pps (7.5 watt). In the moment the location of the implant is marked it is recommended to reemploy the rotary instrument. 8 An Er:YAG laser has been determined as the most suitable platform for this procedure. The Erbium family of lasers is the only one which delivers a tissue-cooling water spray together with the laser beam, an extremely important feature when lasing bone tissue 10,2425. The tip of choice was a 1300 microns sapphire, using non-contact mode. The distance between the end of the tip and the target tissue should be 9mm. The energy used for this procedure was 200 milliJoules / 15 PPS, (3W average power). The headpiece should be always in constant motion very close attention paid, because the bone of the lateral window is usually very thin. The Er:YAG laser does not provide good hemostasis, both because of its short interaction time and its shallow depth of penetration. The moment a little bleeding appears, or the Schneiderian membrane is seen, the laser beam should be moved forward. The closer the beam comes to the Schneiderian membrane, the greater the distance should be between the tip and the target tissue (the energy is controlled by the distance between the end of the tip and target tissue). Pressurized air in the water spray was directed away

from the attachment of the flap to minimize the risk of an air embolism. Antrostomy was performed with the Erbium laser to create a rectangular shape²⁶. The height of this window should not exceed the width of the sinus. After lasing all four flanks of the window, the bone was gently removed or pushed inside the sinus, taking care not to damage the Schneiderian membrane²⁷. The sinus membrane was then lifted gently from the bony floor. A space was created after the sinus membrane has been elevated, which was then grafted with different material.

Experience has shown that the laser is safer to surrounding tissue than rotating instruments^{27, 28, 29} particularly when it comes to the risk of perforating the Schneiderian membrane. When adhering to the recommended operating parameters and tools (energy, tips, hand piece configuration and mode of beam application - contact/non-contact). 9 Periimplantitis is an inflammatory reaction that is associated with the presence of a sub-marginal biofilm, with advanced breakdown of soft and hard tissues surrounding the endosseous implant: loss of the bony support of the implant³⁰.

Therapeutic objectives focus on correcting technical defects by means of surgery and decontamination techniques: REJUVENATING. Removing mobile implants is recommended.

Therapeutic and surgical approaches in the conventional system include:

1. Systemic administration of antibiotics
2. Removal of supra-gingival bacterial plaque
3. Removal of granulation tissue with plastic curettes
4. Detoxification of the exposed surface³¹
 - _Mechanical brushing
 - _Air powder abrasive

Fig. 19_drilling for the implant

Fig. 20_Insertion of the implant

Fig. 21_The erbium to open the lateral window

Fig. 22_The lateral window performed with the erbium

Fig. 23_The erbium to ablate the granulation tissue

Fig. 24_Detoxification of the infected implant screw

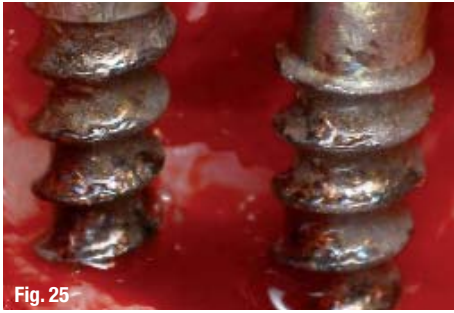

Fig. 25

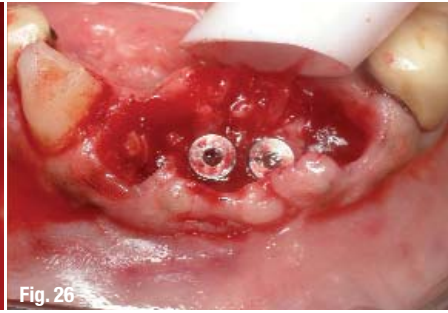

Fig. 26

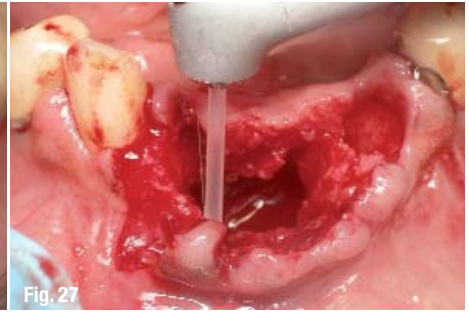


Fig. 27

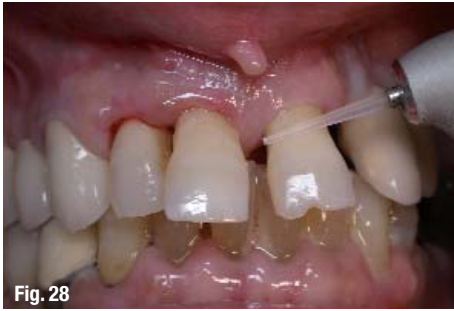

Fig. 28

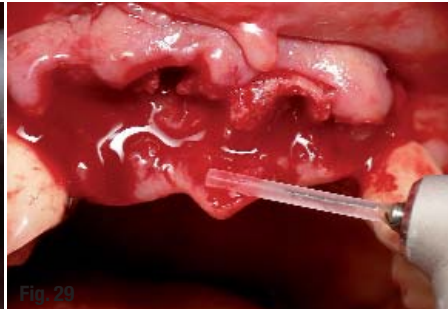


Fig. 29

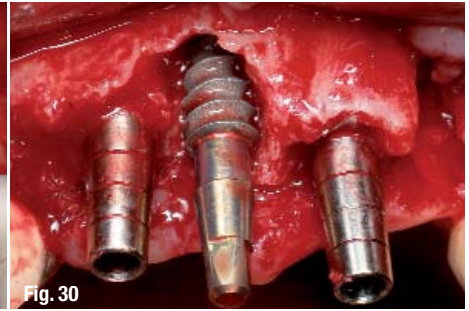


Fig. 30

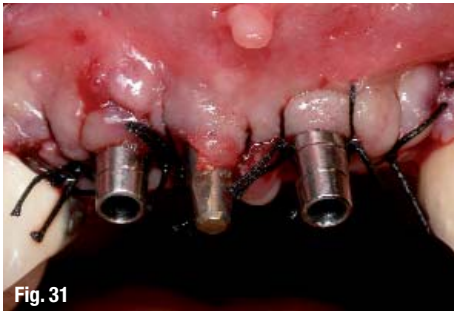

Fig. 31

- Fig. 25_The exposed screw after detoxification
- Fig. 26_Two mobile implants engage each other
- Fig. 27_The erbium to ablate and decontaminate the site
- Fig. 28_At presentation
- Fig. 29_The erbium to ablate granulation tissue and decontamination
- Fig. 30_Immediate implants
- Fig. 31_Immediate implants

- _Citric acid 41
- _Chlorhexidine
- _Delmopinol
- _Topical tetracycline application
- _Low intensity UV-radiation
- 5. Removal of peri-implant pocket
- 6. Regeneration of peri-implant hard tissue (GBR)
- 7. Plaque control

In addition to conventional treatment modalities, the use of the Er:YAG laser has been increasingly promoted for the treatment of peri-implantitis:

- _The Erbium laser can make an incision for flap lifting,
- _Vaporization of granulation tissue
- _Detoxification of the implant surface³² by lasing directly on the implant's exposed screws, using a low-energy setting, the target tissue is disinfected together with the implant surface¹⁵ without injuring their surfaces³³⁻³⁵.

_The laser is bactericidal^{36,37}. The significant bacterial reduction in the implant surface and the peri-implant tissues during irradiation are the main reasons for the erbium laser application in the treatment of peri-implant lesions.

_Ablating the bone with the Er:YAG laser: remodeling, shaping and ablating necrosis Bone^{38,39,40,14}

10- In implants failure sites treatment the Er:YAG laser assist the doctor by the mean of incision to open the flap, ablation of granulation tissue, ablation of necrotic bone and decontamination of the site for GBR

technique.

11-Insertion of implants in infected sites presents a lot of problems and some times require 2 stages of surgery. In conventional methods there is no tool in which in the same time provides decontamination of the target tissue: By lasing with the erbium it is possible to gain decontamination of the infected site, which enables the doctor to save chair time and, in some of the cases, to avoid the second stage of implant surgery.

_Summary

Er:YAG laser is an essential and indispensable tool for implant surgery today.

This wavelength shows promise and safe as an effective new technical modality for implant therapy when adhering to the recommended operating parameters and tools (Energy, tips, hand piece configuration and mode of beam application - contact/non-contact). However, further clinical and basic investigations are requiring for establishing the clinical effectiveness and safety of the Er: YAG laser in implant site preparation._

The Literature list can be requested from the editorial office.

_contact	laser
<p>Dr Avi Reyhanian Private Clinic ,Netanya, Israel 1 Shaar Haemek St. Netanya 42292, Israel Office: +972-9-8338825 Fax: +972-9-8339890 E-mail: avi5000rey@gmail.com Web: www.avidentallaser.com</p>	