

Removal of a fibroma using an Er:YAG laser

Dr Sigalit Blumer, Israel & Prof. Roly Kornblit, Italy

Case presentation

A healthy 8-year-old boy was referred to the Department of Pediatric Dentistry at Tel Aviv University in Israel for lesion removal and excisional biopsy. The boy came to our clinic complaining about a lesion on the lower lip. A few months prior to that, he had sustained an injury to the lower lip that was followed by the appearance of a raised lesion on the inside of the lip on the left. According to the father, the boy would bite on the protruding lesion, resulting in secondary trauma that caused the lesion's growth and thickening. However, the lesion was not painful. According to the parents, the boy apparently had a high pain threshold and thus did not feel pain when biting on the lesion. Upon intraoral examination (Fig. 1), a lesion of 6mm in diameter and protruding approximately 3mm

from the mucosa was visible. The lesion was round, symmetrical, not ulcerated, pinkish in colour and firm to the touch. The patient had no underlying diseases, nor did he take any medications on a regular basis.

Treatment options

We had two possible options for treatment at our disposal: either a surgical removal of the lesion by excision with a scalpel and suturing to stop the bleeding or surgical removal by laser. The option of laser-assisted treatment was chosen because of its significant advantages over the use of a scalpel. Firstly, this modality has a marked capability of disinfection of the treated and surrounding tissue during surgery, which results in a reduced risk of postoperative inflammation and thus the need for anti-

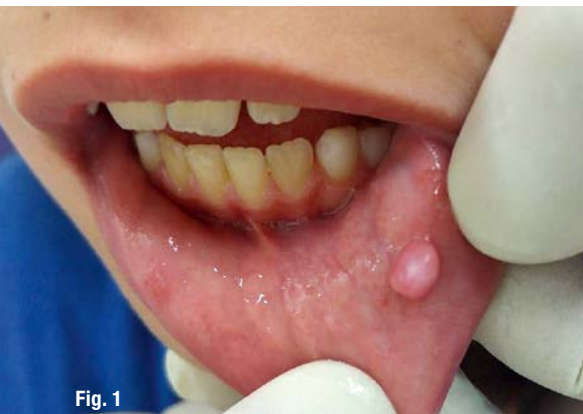

Fig. 1

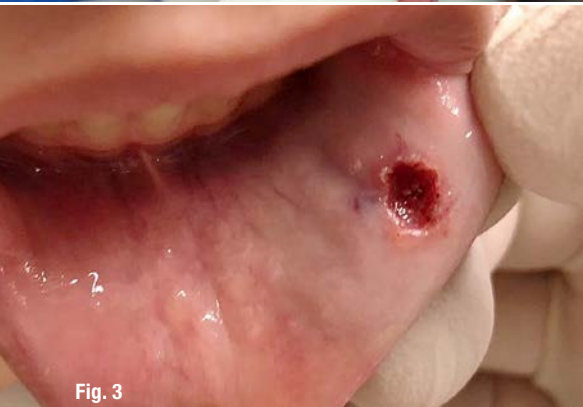

Fig. 3

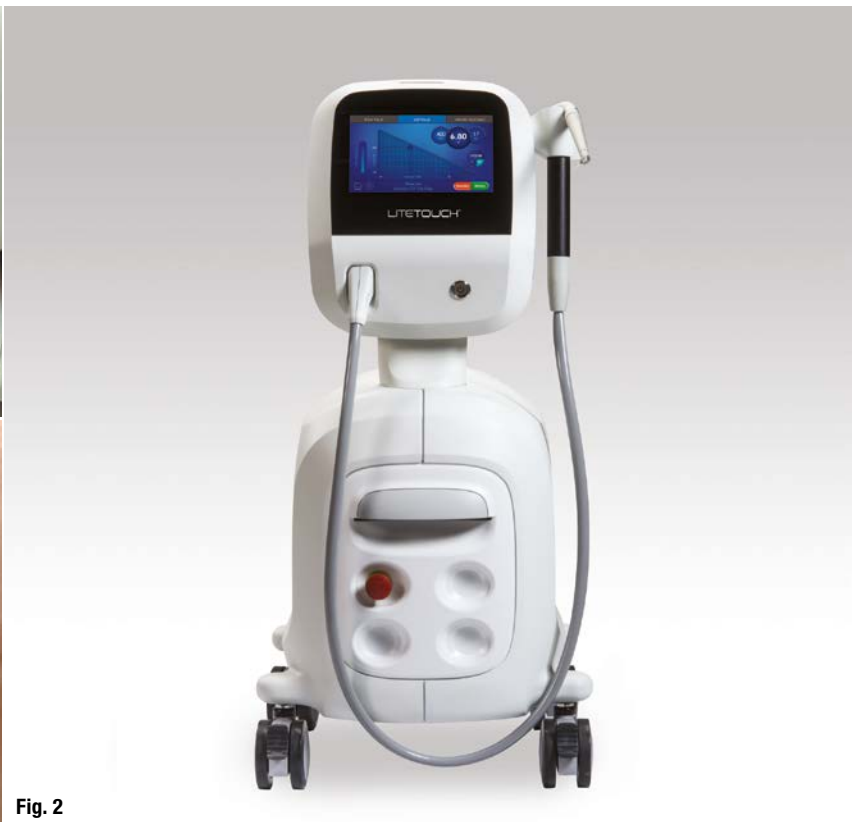

Fig. 2

Fig. 1: The lesion prior to its removal. **Fig. 2:** The LiteTouch Er:YAG laser from Light Instruments. **Fig. 3:** The lesion immediately after the surgery.

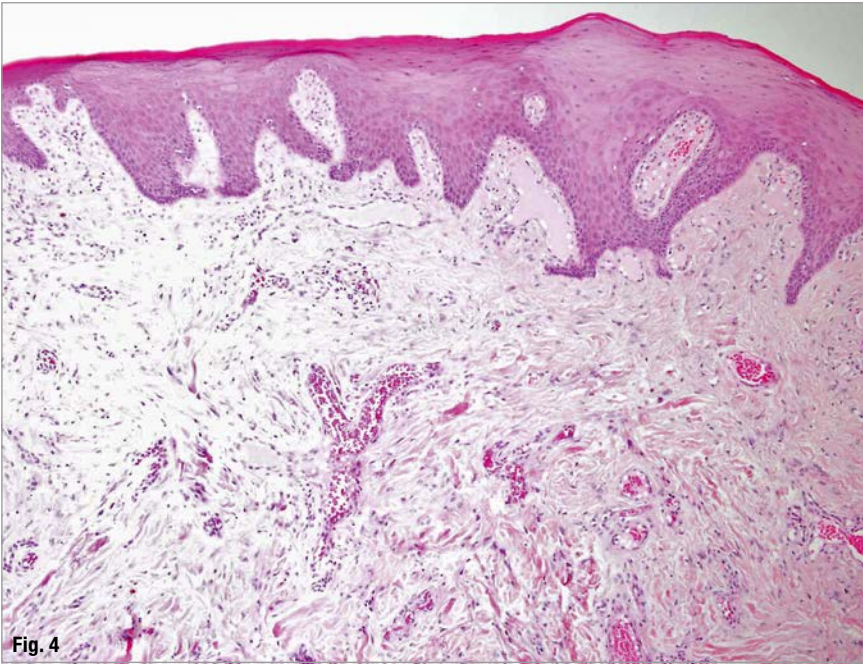


Fig. 4

Fig. 4: Histology of the lesion.

biotics. Secondly, a laser treatment has the ability to increase the metabolic activity, resulting in faster healing. Thirdly, there is the advantage of the rapid stopping of postoperative bleeding and, therefore, no sutures are needed. Lastly, postoperative pain can be avoided with a laser treatment.

On the Er:YAG laser

We chose to use the 2,940 nm Er:YAG laser (LiteTouch, Light Instruments, Fig. 2) for the surgery. The energy of this wavelength is well absorbed by water and hydroxyapatite. Regarding paediatric dentistry, this wavelength can be used for treatment of hard tissue, such as sealing pits and fissures, and removing caries and tooth pulp. Moreover, it can be used for the treatment of soft tissue, such as fraenectomy, gingivectomy, gingivoplasty, operculectomy, disinfection of periodontal pockets, irradiation of aphthous lesions and removal of other lesions. Furthermore, the Er:YAG laser was chosen owing to its advantages in soft-tissue surgery in comparison with other wavelengths: the energy does not penetrate too deep into the tissue and does not disperse into or damage the surrounding tissue, which results in the treatment being minimally invasive and

very quick, yet effective. When treating soft tissue, the Er:YAG laser can be used with or without air or water spray cooling.

The operative phase

Firstly, we used nitrous oxide in order to reduce the patient's fear regarding the operation and to improve his cooperation. We then began locally anaesthetising the area surrounding the lesion, using 0.9 ml of 2% lidocaine with a vasoconstrictor. With regard to the surgery, we used low-energy surgical parameters of 150 mJ, 1.5 W and 10 Hz, and omitted the spraying of air or water. The use of the lowest effective energy parameters should always be preferred in order not to traumatise the treated tissue and to avoid any damage to the surrounding area. If needed, the energy parameters can be gradually raised.

In this particular case, the use of cooling water spray was not necessary because the laser was applied to soft tissue that was relatively distant from the teeth and, thus, there was no risk of overheating the pulp. The lack of water cooling and the long laser pulse duration contributed to energy accumulation in the underlying tissue, thus avoiding bleed-

ing. The lesion was held with surgical forceps, and the laser beam was focused around the lesion using a tip of 0.6mm in diameter and 17.0mm in length in contact, while leaving safety margins of approximately 3.0mm for a correct subsequent histological examination. The working movements were continuous and repetitive, in contact with the lesion, which resulted in quick and efficient disengagement of the lesion. Moreover, the treatment was accompanied by high-intensity suction.

After the operation

After its removal, the lesion was sent for histological examination. Furthermore, the laser parameters were then lowered to sub-ablative energies of 20mJ, 0.2W and 10Hz (gentle treatment mode), and a larger tip of 1.3mm in diameter and 17.0mm in length was used in order to disperse superficial heat to stop the bleeding, and as a result, coagulation in the area could be achieved. In this regard, the movements were slow and repetitive, and a gauze pad was used to check whether the bleeding had stopped. After 60 seconds, the bleeding had stopped and no coagulating agent was needed. We decided not to suture the area in order to prevent potential scarring, to reduce the accumulation of food residue around the suture, to reduce interference when eating and talking, and to decrease secondary trauma to the tissue and the patient.

The boy's behaviour throughout the treatment was excellent. He felt comfortable and did not feel any pain. He stated that he was relaxed throughout the surgery and had an overall pleasant experience. Four days after the treatment, the lesion area had been covered by fibrin, and the lesion margins appeared to have contracted (Fig. 3). After about a week, a crust formed and there were no signs of scarring. The tissue healed entirely. The biopsy of the lesion showed that it was in fact a fibroma (a high-den-

sity connective tissue with multiple blood vessels, chronic inflammatory cells and several nerve fibres; Fig. 4).

Conclusion

The use of the LiteTouch Er:YAG laser proved to be an excellent alternative to two procedures in paediatric dentistry. In this particular case, we reported the removal of a raised lesion (fibroma) that was formed after an injury to the lower lip followed by constant irritation. The lesion, which was of considerable proportions, bothered the child and interfered with his oral activities. Hence, it was necessary to remove it and to obtain an accurate diagnosis regarding its nature. The success of the treatment was manifested by the fact that it was both conservative and quick, did not have to be repeated and did not involve any fear or pain. The child was very cooperative and he and his parents were very satisfied with the treatment being relatively uncomplicated and the tissue healing very rapidly.

Editorial note: We were provided with a short video recording of the surgery portrayed in this article, which can be watched online using the QR code on the right.



contact

Dr Sigalit Blumer
 Department of Pediatric Dentistry
 School of Dental Medicine
 Tel Aviv University
 Tel Aviv, Israel
 blumer@012.net.il



Kurz & bündig

In dem hier dargestellten Fall klagte ein achtjähriger Junge über eine Läsion auf der Innenseite seiner Unterlippe. Der Läsion war eine Verletzung an der Lippe einige Monate zuvor vorausgegangen. Aufgrund seiner hohen Schmerztoleranz hatte der Junge die Läsion regelmäßig zerbissen und zerkaut, wodurch sich die Läsion stetig verhärtete und zunehmend an Größe gewann.

Zur Entfernung der Läsion entschied sich das Ärzteteam um Frau Dr. Sigalit Blumer für den Einsatz eines LightTouch Er:YAG-Lasers der Firma Light Instruments, da dieser signifikante Vorteile gegenüber dem Skalpell hat. Der Eingriff mithilfe eines Lasers birgt beispielsweise kein Risiko einer postoperativen Gewebezündung und es müssen selten Antibiotika im Rahmen einer anschließenden Behandlung verabreicht werden. Darüber hinaus regt der Laser die metabolische Aktivität an, was eine schnellere Wundheilung zur Folge hat.

Der operative Eingriff war von kurzer Dauer, sehr effektiv und schmerzfrei für den zu behandelnden Jungen, da diesem im Vorfeld Distickstoffmonoxid verabreicht und die betroffene Stelle im Mundraum lokal betäubt worden war. Im Anschluss wurde eine histologische Biopsie der entfernten Läsion durchgeführt, wodurch festgestellt werden konnte, dass es sich um ein Fibrom – also dichtes Bindegewebe – bestehend aus einer Vielzahl an Blutgefäßen, chronischen Entzündungszellen sowie mehreren Nervenfasern, handelte. Der Erfolg der Behandlung zeigte, dass der Einsatz des LiteTouch Er:YAG-Lasers eine gute Alternative zu konventionellen Behandlungsmethoden darstellt.